

Spontaneous extensor pollicis longus (EPL) tendon rupture after ironing

Spontaneous EPL rupture

Serdar Karaman¹, Muhammed Köroğlu², Zeynep Maraş Özdemir³, Kadir Ertem¹¹Department of Orthopedics and Traumatology, Medicine Faculty of İnönü University, Malatya²Kilis State Hospital, Kilis³Department of Radiology, Medicine Faculty of İnönü University, Malatya, Turkey**Abstract**

Spontaneous tendon ruptures can occur rarely. Distal radius fractures, steroid applications and systemic diseases are mostly attributed to its etiology. In the treatment of spontaneous tendon ruptures, primary repair is not possible and tendon transfer is often required. The EPL tendon is the main extensor of the thumb. This muscle originates from the interosseous membrane, especially the dorsal part of the ulna. The EPL passes from the third dorsal extensor compartment ulnar to the Lister's tubercle before returning to the thumb. Since spontaneous tendon ruptures often occur due to degeneration, the defect is large in the area of the rupture. Therefore, spontaneous tendon ruptures are treated with tendon transfer rather than end-to-end repair. In this case report, we aimed to present a case of extensor indicis proprius (EIP) tendon transfer to our 64-year-old female housewife who was admitted to our clinic with a spontaneous rupture of the EPL tendon a resulting from excessive ironing in a short term. As a result of the examination and radiological evaluation of the patient who applied to our clinic with the complaint of inability to extend the thumb extension, a spontaneous EPL tendon rupture was diagnosed and surgical treatment was decided. While making a diagnosis of spontaneous tendon rupture, it was learned that the patient had no trauma and rheumatologic disease in her anamnesis. Ultrasound and magnetic resonance imaging (MRI) were used to confirm the diagnosis radiologically. The spontaneous EPL tendon rupture treatment was successfully provided by the transfer of the extensor indicis proprius (EIP) tendon. At the six month of follow-up after the surgical treatment, it was observed that the finger regained its former function. In elderly patients, repetitive, forceful finger movements for a long time may cause spontaneous tendon rupture. Long-term coercive thumb movement is a risk factor for EPL spontaneous tendon rupture.

Keywords

Spontaneous tendon rupture; Extensor pollicis longus (EPL); Tendon transfer

DOI: 10.4328/ACAM.20386 Received: 2020-10-29 Accepted: 2020-12-01 Published Online: 2020-12-11 Printed: 2021-06-01 Ann Clin Anal Med 2021;12(6):704-707

Corresponding Author: Serdar Karaman, Department of Orthopedics and Traumatology, Medicine Faculty of İnönü University, 44280, Battalgazi, Malatya, Turkey.

E-mail: drserdarkaraman@gmail.com P: +90 5373040091

Corresponding Author ORCID ID: <https://orcid.org/0000-0002-5546-3649>

Introduction

EPL tendon rupture is known to occur spontaneously after fractures, as a result of drug applications such as steroids, repetitive and excessive abnormal motion of the wrist joint, rheumatoid arthritis and atypical etiology that are also mentioned in the literature. [1]

Extensor pollicis longus (EPL) is a skeletal muscle that follows a complex anatomical course in human hands. The EPL is responsible for the extension of the terminal phalanx of the thumb and adds the first metacarpal. This muscle originates from the interosseous membrane, especially the dorsal part of the ulna. The EPL passes from the third dorsal extensor compartment ulnar to the Lister's tubercle before returning to the thumb. The anterior interosseous artery supplies the first part of the EPL tendon before the synovial sheath. The radial artery supplies the tendon after the synovial sheath. The vascularity of the tendon in the third compartment of the Lister tubercle is weak or avascular. [2] The tendon of a watershed area with limited blood flow is at risk of ischemia and consequent tendon degeneration. As a matter of fact, we shared the case of spontaneous EPL rupture due to repetitive motion after degeneration, which is an atypical etiology. It is known that end-to-end repair cannot be performed in spontaneous ruptures, thus it is treated with tendon transfer. Clinical examination is very significant in diagnosing a tendon rupture, and ultrasound and magnetic resonance (MR) can confirm the diagnosis.

Case Report

A 64-year-old female patient was admitted to our clinic with complaints of inability to use her thumb. When diagnosis of spontaneous tendon rupture was made, it was learned that the patient had no history of trauma or rheumatologic disease. The situation that is meaningful in the story; we've learned that for the past ten days she has been ironing every day and using her thumb to release the steam boosting from the iron. It was learned that while using her thumb, she suddenly had a sense of detachment at the wrist level and could not lift her thumb.

In the examination, the patient was unable to actively extend her thumb, and the flexion action was complete. The patient had no known systemic disease other than hypertension and obesity. In the patient's medical history, there was endoscopic median nerve decompression due to the bilateral carpal tunnel four years ago, and high tibia osteotomy for both knees due to medial gonarthrosis 10 years ago. The patient who had no rheumatologic disease had a sedimentation rate of 18mm / h (normal value 0-20), c-reactive protein value of 0.41mm / dl (normal value 0-0.35) and a rheumatoid factor of 22.8 (normal value 0-20). Although the rheumatoid factor value was positive, there were no clinical findings. There is no osseous pathology in X-ray imaging. After examination with ultrasound and magnetic resonance (MR) of the wrist, the extensor pollicis longus tendon was found to have a full-thickness rupture in the 3rd extensor compartment and there was a 3 cm gap at the level of the Lister's tubercle and distally (Figure 1).

After a sterile environment suitable for surgical operation under axillary-block anesthesia, a slightly oblique dorsal incision over the third extensor compartment was performed and a full-thickness rupture of the EPL tendon and the fibrotic thickening were observed, the fibrotic part was excised and sent to the pathology. Then the EIP tendon was detected by entering the wrist through the dorsal extensor crisis. The EIP tendon was excised by cutting the dorsal second metacarpophalangeal (MCP) joint level. Then, the EIP tendon was transferred to the EPL tendon with Pulvertaft method, and the thumb extension tone was maintained with sufficient tension. The incisions were closed in a standart fashion (Figure 2a, 2b, 2c, 2d).

A short arm thumb splint was applied at the appropriate extension level. The pathology report was evaluated as fibrosis and a chronic inflammatory event. The splint was preserved for 6 weeks, after which the rehabilitation procedure was started. At the 6th month of the postoperative period, the patient had active extension of up to forty degrees on the 1st finger (Figure 2e, 2f).

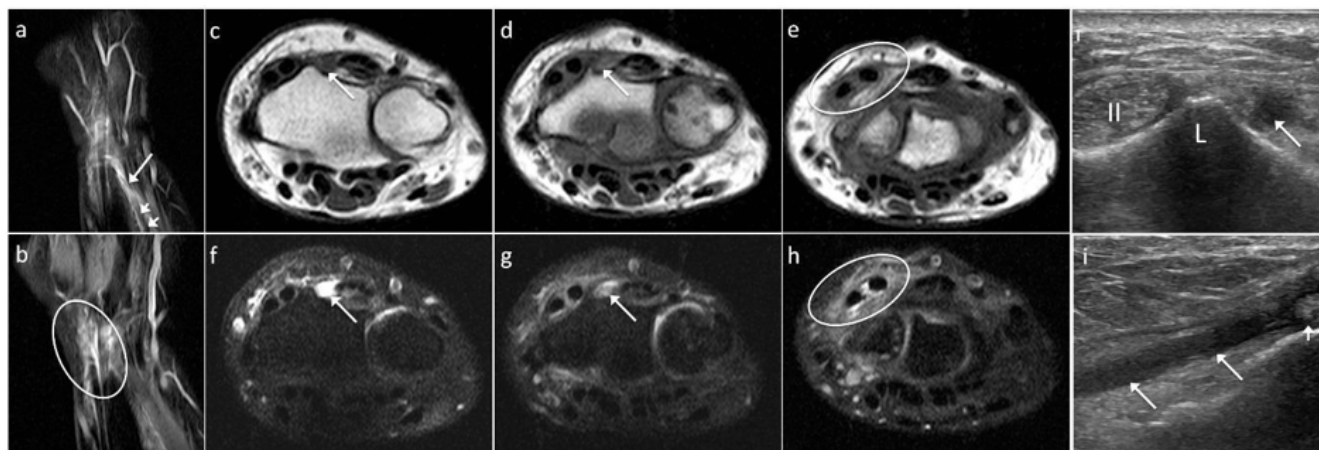


Figure 1. Ultrasound and magnetic resonance images. Coronal proton-density (PD) fat-saturated (a), axial T1-weighted (c, d), and axial PD fat-saturated (f, g) magnetic resonance (MR) images show fluid signal intensity instead of the normal tendon structure due to rupture in the third extensor tendon compartment (long arrows). Synovial effusion and surrounding soft tissue edema are also seen in the tendon sheath of the second extensor compartment on the same images (circles). Ultrasound examination in axial plane (i), at Lister's tubercle (L), shows the absence of EPL tendon (long arrow) adjacent to the second extensor compartment (II). Longitudinal ultrasound image (j) demonstrates hypochoic echogenity (long arrows) representing torn tendon fibers and fluid in the tenosynovial sheath. The retracted proximal end of EPL tendon is seen on both coronal PD fat-saturated MR (b) and longitudinal ultrasound images (j) (short arrows).

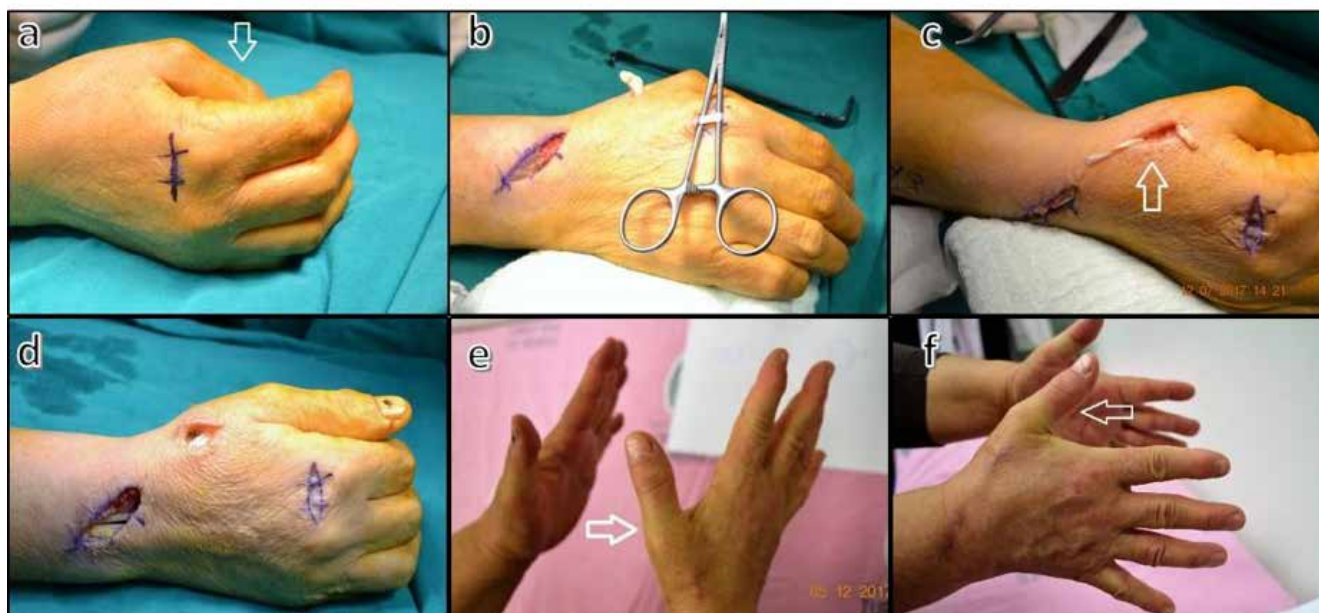


Figure 2. Preop, intraop and postop images. The position of thumb while resting hand (short arrow) (a). Eip tendon exposure and proximal part of EPL tendon (b). Epl distal part and EIP tendon (short arrow) (c). The tendon transfer was completed and thumb extension tone was maintained with sufficient tension (d). Right hand thumb position at oblique view (long arrow) (e). Right hand thumb position at lateral view (long arrow) (f)

Discussion

Etiology of spontaneous tendon rupture: plaque and fixator applied to the radius, systemic diseases and steroid injection should be kept in mind in the spontaneous degenerative process. In our case, there was no history of trauma, no steroid injection, no systemic disease. Among the rare causes of EPL tendon rupture, dorsal ulna dislocation, madelung deformity, and necrotic scaphoid fracture have been previously reported in the literature. [3] A case of spontaneous EPL rupture due to calcific tendinitis was reported. [4] In Kannus' study, 97% of spontaneous tendon ruptures were found to be degenerative, and in our case, this pathology was supported. [5] The treatment of spontaneous EPL rupture was reviewed, and surgical options tried included direct repair, tendon transfer, and tendon grafting. Direct end-to-end repair is difficult because rupture tip is often fragile and thin. After removing the unhealthy part, there is always a gap between the proximal and distal end. Tendon transfer or tendon graft has become the standard procedure. When it comes to tendon transfer, EIP transfer is the standard technique for spontaneous EPL rupture. If the EIP tendon cannot be used, the palmaris longus (PL) tendon can be used as a graft [6]. In our case, the EIP transfer was done and the satisfaction was provided. Jun and his colleagues in the case report also worked as a seamstress and repeated the same movement for a long time in a patient who was referred to the EPL rupture and tendon transfer [1]. Our patient was a housewife, but in the last period she had been ironing for a long time. One cadaveric study suggested that a direct crush injury to the EPL can occur as a result of contact between the Lister tubercle and the base of the third metacarpal bone in a simulated fall onto an outstretched hand [7]. In a retrospective study on eight patients with EPL tendon rupture, 4 patients were found to have an EPL tendon rupture without bone fracture. These 4 patients had a history of falling on the wrist [6]. Due to the anatomical structure of the EPL tendon and its nutrition at the wrist level, spontaneous rupture is more common than other tendons [2, 7].

Our patient had no history of falling on the wrist. Zviac et al. observed spontaneous rupture of the EPL tendon in patients without severe trauma or inflammatory diseases, Lister tubercle abnormalities, synovitis and tenosynovitis, and concluded that EPL tendon rupture can occur without trauma due to abrasion of the tendon around the Lister tubercle, regardless of age [8]. Our patient tested positive for rheumatoid factor, but the patient had no symptoms of rheumatoid arthritis such as morning stiffness, did not meet the diagnostic standard, and synovitis was not observed during the operation. The patient had ironed at home for a long time in recent days. However, this patient was a housewife and became the first patient to spontaneously rupture the extensor due to repetitive movements while long time ironing.

Conclusion

In elderly patients, repetitive forceful finger movements for a long time may cause spontaneous tendon rupture. Long-term coercive thumb movement is a risk factor for EPL spontaneous tendon rupture. Spontaneous tendon rupture is not rare and has nearly complete function with appropriate surgical treatment.

Clinical messages

Spontaneous tendon ruptures should be in our mind in any situation limiting movement without trauma. While questioning the etiology, it should be kept in mind that tendon rupture can be caused by atypical causes.

Scientific Responsibility Statement

The authors declare that they are responsible for the article's scientific content including study design, data collection, analysis and interpretation, writing, some of the main line, or all of the preparation and scientific review of the contents and approval of the final version of the article.

Animal and human rights statement

All procedures performed in this study were in accordance with the ethical standards of the institutional and/or national research committee and with the 1964 Helsinki declaration and its later amendments or comparable ethical standards. No animal or human studies were carried out by the authors for this article.

Conflict of interest

None of the authors received any type of financial support that could be considered potential conflict of interest regarding the manuscript or its submission.

References

1. Choi JC, Kim WS, Na HY, Lee YS, Song WS, Kim DH, et al. Yae Hoon Park. Spontaneous rupture of the extensor pollicis longus tendon in a tailor. *Clin Orthop Surg*. 2011; 3(2):167-9.
2. Hirasawa Y, Katsumi Y, Akiyoshi T, Tamai K, Tokioka T. Clinical and microangiographic studies on rupture of the E.P.L. tendon after distal radial fractures. *J Hand Surg Br*. 1990; 15(1):51-7.
3. Harvey FJ, HARvey PM. Three rare causes of extensor tendon rupture. *J Hand Surg Am*. 1989; 14(6):957-62.
4. Ertem K, Özdemir ZM, Görmeli G, Köroğlu M. Attritional rupture of the extensor pollicis longus tendon due to calcified extensor carpi radialis tendon group: a case report. *Joint Diseases and Related Surgery*. 2017; 28(1):59-61.
5. Kannus P, Jozsa L. Histopathological changes preceding spontaneous rupture of a tendon. A controlled study of 891 patients. *J Bone Joint Surg Am*. 1991; 73(10):1507-25.
6. Hu C-H, Fufa D, Hsu C-C, Lin Y-T, Lin C-H. Revisiting spontaneous rupture of the extensor pollicis longus tendon: eight cases without identifiable predisposing factor. *Hand (N Y)*. 2015; 10(4): 726–31.
7. Ferreres A, Llusá M, García-Elías M, Lluch A. A possible mechanism of direct injury to the EPL tendon at Lister's tubercle during falls with the wrist fully extended. *J Hand Surg Eur Vol*. 2008; 33(2):149-51.
8. Zvijac JE, Janecki CJ, Supple KM. Non-traumatic spontaneous rupture of the extensor pollicis longus tendon. *Orthopedics*. 1993; 16(12):1347-50.

How to cite this article:

Serdar Karaman, Muhammed Köroğlu, Zeynep Maraş Özdemir, Kadir Ertem. Spontaneous extensor pollicis longus (EPL) tendon rupture after ironing for a long time: A case report. *Ann Clin Anal Med* 2021;12(6):704-707